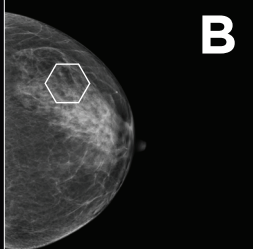
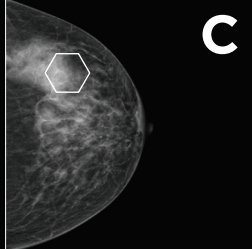
**A****Almost entirely fatty**

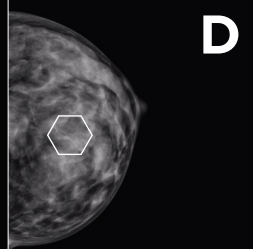
There is no dense tissue which makes abnormalities easy to detect.

**B****Scattered fibroglandular densities**

Scattered areas of density but majority of tissue is fatty.

**C****Heterogeneously dense**

More than half the breast is dense tissue.

**D****Extremely dense**

Nearly all of the tissue is dense.