

# Shear Wave Elastography

Mayfair Diagnostics offers a sub-specialized, multidisciplinary ultrasound service called shear wave elastography. This community-accessible liver study has a number of advantages:

Detecting fibrosis earlier than other imaging tests	Assessing a larger portion of the liver compared to liver biopsy	Examining morphologic changes of the liver and signs of portal hypertension concurrently	The ability to be performed in those with high BMI or ascites	Cost effective
---	--	--	---	----------------

**Shear wave elastography (SWE)** provides a non-invasive assessment of liver fibrosis by quantifying liver tissue stiffness. It directs painless, low-frequency vibrations into the liver, creating a visual map of liver stiffness and providing a quantitative measurement. The preparation for this study is the same as an abdominal ultrasound exam.

## Conditions leading to liver fibrosis

### Nonalcoholic fatty liver disease (NAFLD)

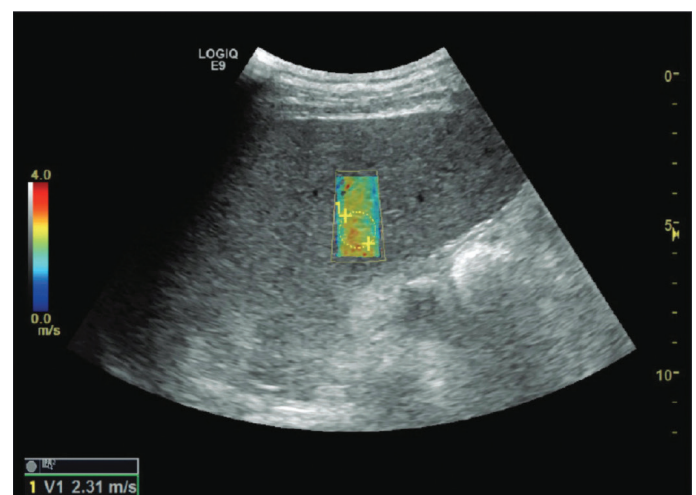
Umbrella term that encompasses a full spectrum of fatty liver disease in those who drink little to no alcohol and includes simple steatosis, non-alcoholic steatohepatitis (NASH), and fatty liver with fibrosis/cirrhosis. It's the most common liver disease in Canada, occurring in 25% of the population.<sup>1</sup>

Risks associated with NAFLD/NASH:

- Cellular inflammation leads to scarring.
- NASH can lead to cirrhosis, hepatocellular carcinoma (HCC), and liver failure with the need for liver transplantation.
- It can be difficult to distinguish between steatosis, steatohepatitis, and cirrhosis clinically and with conventional imaging methods.
- Identification of significant liver fibrosis is important for prognosis, surveillance, and management options.

## Other causes of chronic liver disease

Excessive alcohol use, viral hepatitis, autoimmune and genetic disorders, medication, and toxic chemicals can all lead to chronic liver disease. They result in a similar common pathway of cellular inflammation leading to scarring and fibrosis of the liver. Patients with liver disease may not have symptoms or may have vague symptoms (e.g. abdominal pain, fatigue, etc.).



Pictured above: High liver Shear Wave speed measured in a patient with Child-Pugh A cirrhosis. Image courtesy of GE Healthcare.

## Diagnosing Liver Fibrosis

Liver biopsy is the gold standard for staging of liver fibrosis, but it's invasive, carries a small risk of complication, and there is interobserver and sampling variability. Plus, high prevalence of NAFLD and the need for longitudinal monitoring makes liver biopsy not feasible in all patients.

Due to these considerations, non-invasive techniques have become more popular and include biochemical tests, transient elastography (FibroScan®), MR elastography, and, of course, shear wave elastography.

### When to refer for elastography

Elastography is appropriate for the following indications:

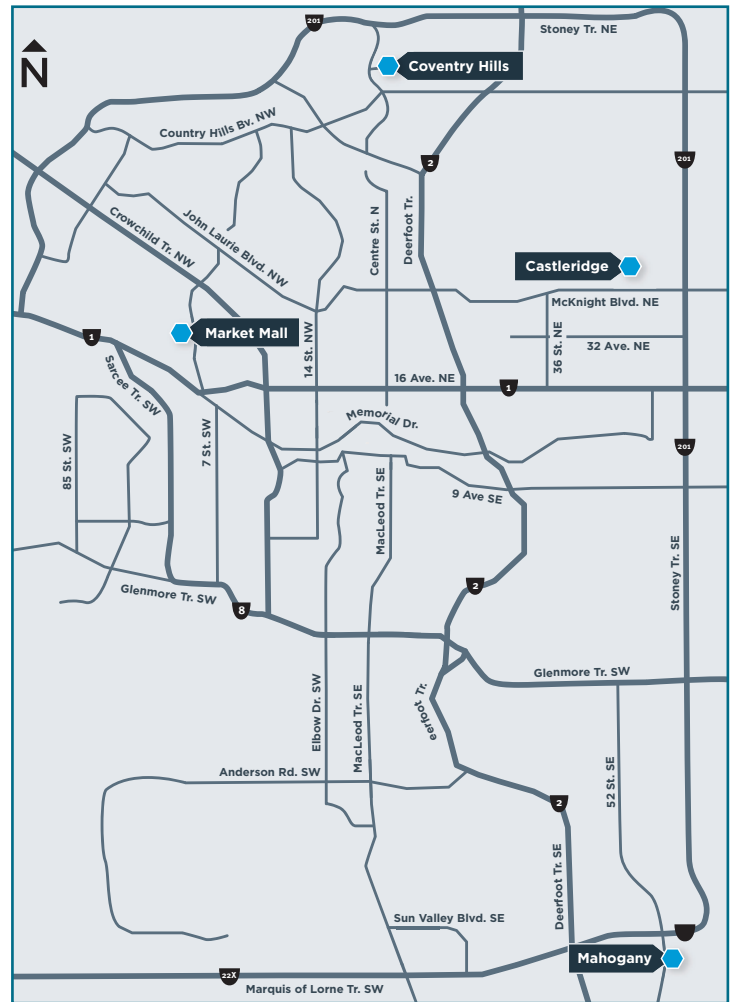- Suspected or known NAFLD (Hepatology NAFLD pathway, [specialistlink.ca](http://specialistlink.ca)):
  - Risk factors for NAFLD (obesity, Type II diabetes, hyperlipidemia, metabolic syndrome, etc.).
  - Fatty liver found on imaging (CT, MRI, ultrasound, etc.).
  - Abnormal ALT or AST.
- Excessive alcohol consumption.
- Other causes of chronic liver disease (e.g. viral hepatitis, hemochromatosis, autoimmune disorders, etc.).

SWE exam protocol and interpretation are performed according to the Society of Radiologists of Ultrasound Consensus Statement on Elastography.<sup>1</sup>

- Five to 10 measurements are obtained.
- Interquartile range-to-median (IQR/M) shows variability in measurements.
- IQR/M <30% means the quality of the measurements are satisfactory and the exam is valid. This value is provided on the report.

Results will indicate if there is a high probability of the liver being normal, if there's suggestion of compensated advanced chronic liver disease or clinically significant portal hypertension, or if further confirmatory testing is needed such as liver biopsy.

<sup>1</sup> Barr RG, Wilson SR, Rubens D, et al. "Update to the Society of Radiologists of Ultrasound Liver Elastography Consensus Statement." *Radiology* 2020; 296:263-274.



## Mayfair Diagnostics Clinic Locations



ELASTOGRAPHY  
LOCATIONS

### Castleridge Plaza

20, 55 Castleridge Blvd. NE

### Coventry Hills

457, 130 Country Village Road NE

### Mahogany Village

230, 3 Mahogany Row SE

### Market Mall

333, 4935 - 40 Ave. NW

Rev. 05/2023